



Cover image

Arthroscopic visualization of the popliteal hiatus and localization of an intraarticular free body

Visualización artroscópica del hiato poplíteo y localización de un cuerpo libre intraarticular

S.V. Campesino-Nieto, G. Useros-Milano, R. Herreros-López, V. Álvarez-García, L.E. Pareja-Corzo

Hospital Universitario Río Hortega. Valladolid (Spain)

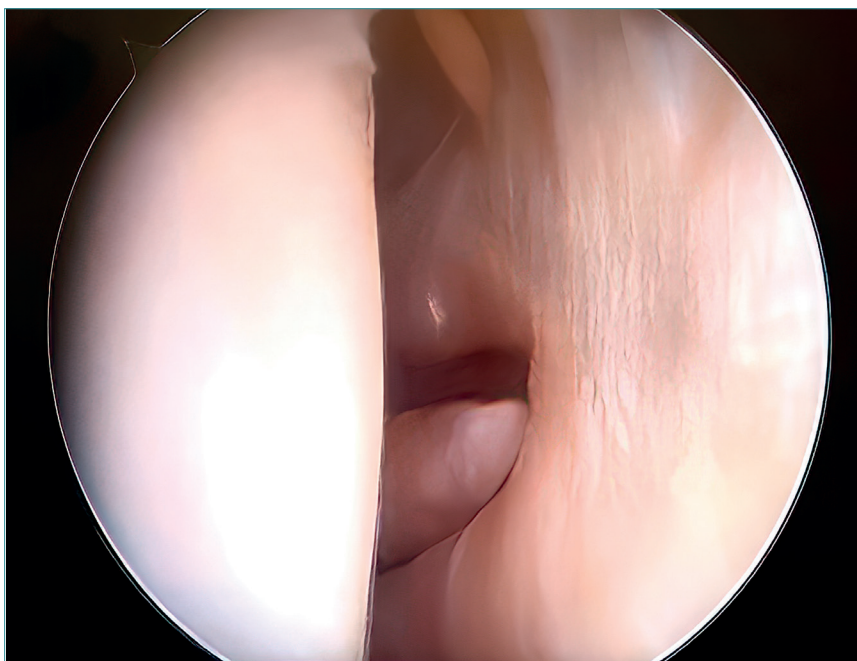
Correspondence:

Dr. Silvia Virginia Campesino-Nieto
E-mail: scampesino@hotmail.com

Received 8 February 2023
Accepted 14 January 2024
Available online: December 2023

Popliteal hiatus in an arthroscopic view of the knee after sliding through the anterolateral portal, with local-

ization and subsequent extraction of an intraarticular free body.



<https://doi.org/10.24129/j.reacae.30380.fs2302008>

© 2023 Fundación Española de Artroscopia. Published by Imaidea Interactiva in FONDOSCIENCE® (www.fondoscience.com). This is an Open Access article under license CC BY-NC-ND (www.creativecommons.org/licenses/by-nc-nd/4.0/).