



**Cover image**

## **Pigmented villonodular synovitis of the ankle** *Sinovitis vellonodular pigmentada de tobillo*

V. Hurtado-Oliver, C. Villanueva-Dolcet, S. Escribano-Zacarés, S. Orenge-Montoliu

*Hospital Comarcal Francesc de Borja. Gandía, Valencia (Spain)*

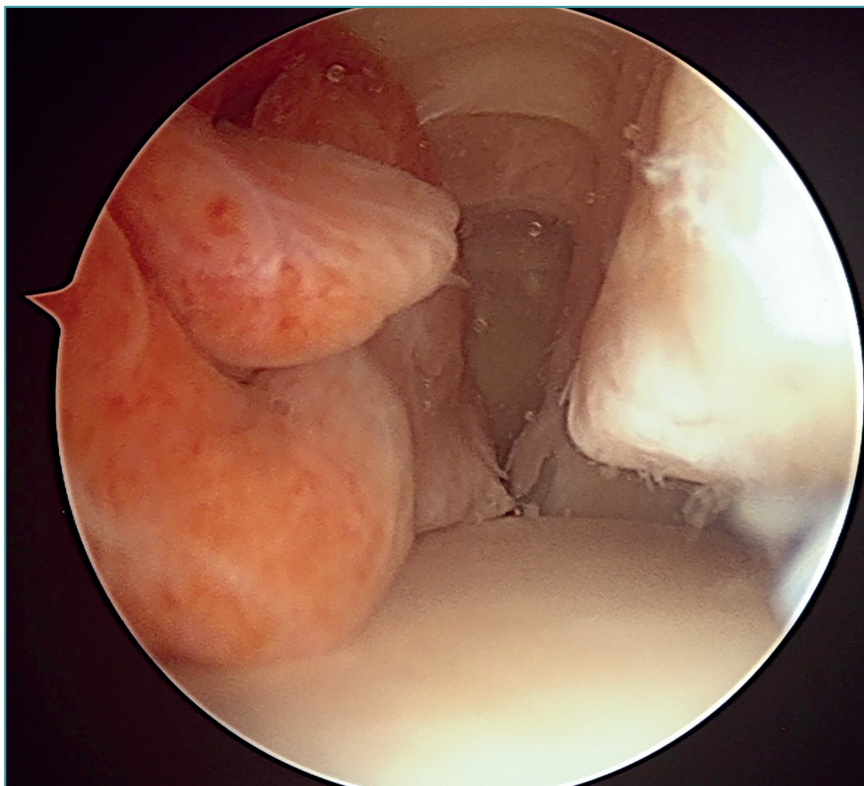
**Correspondence:**

Dr. Vicent Hurtado-Oliver  
E-mail: vicenthurtado@gmail.com

Received 14 July 2020  
Accepted 30 July 2021  
Available online: September 2021

View from the arthroscopic anteromedial portal of the right ankle in lateral direction: a mammillated and hyperemic mass is observed, corresponding to pigmented

villonodular synovitis in the anterior compartment of the ankle, causing a spatial conflict between the dome of the astragalus and the anterodistal border of the tibia.



<https://doi.org/10.24129/j.reaca.28373.fs2007040>

© 2021 Fundación Española de Artroscopia. Published by Imaidea Interactiva in FONDOSCIENCE® ([www.fondoscience.com](http://www.fondoscience.com)). This is an Open Access article under license CC BY-NC-ND ([www.creativecommons.org/licenses/by-nc-nd/4.0/](http://www.creativecommons.org/licenses/by-nc-nd/4.0/)).